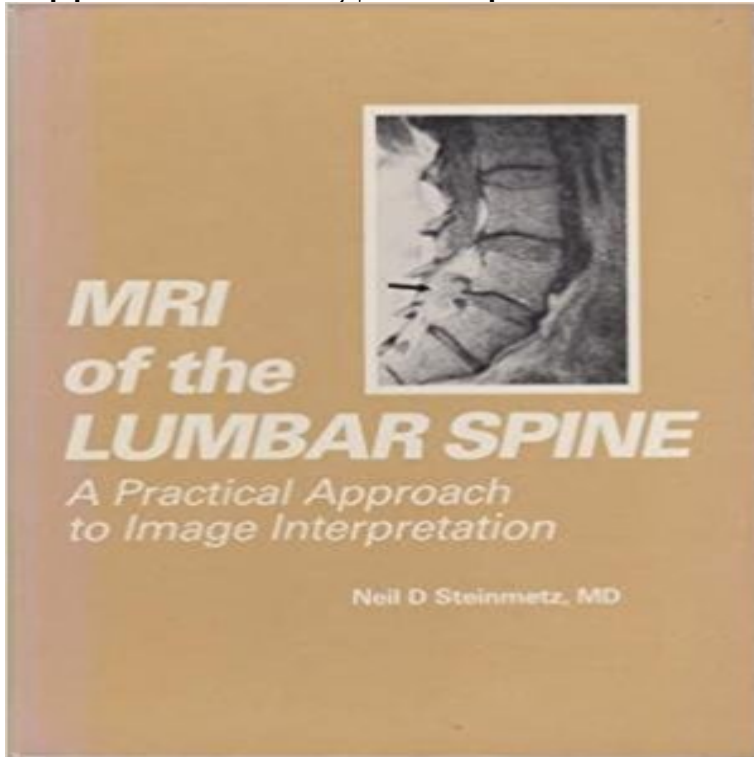


Magnetic Resonance Imaging of the Lumbar Spine: A Practical Approach to Image Interpretation



Please return following links to the footer: Designed by FSF - Fantasy Football Podcast, thanks to: JDis.co, SJThemes.com and SMThemes.com Up SaintPierreDuMont Football LE CLUB ORGANIGRAMMES INFOS UTILES PARTENAIRES DU CLUB CONNEXION HOME ACTUALITÉS ECOLE DE FOOT EQUIPES SÉNIORS ecole de foot ecole de foot U 7 (Moins de 7 ans) U 7 (MOINS DE 7 ANS) Saison 2015 - 2016 U 15 (Equipe 1) U 15 (EQUIPE 1) Saison 2015 - 2016 12 SPORTING CLUB SAINT PIERRE DU MONT FOOTBALL - STADE DE MÃNASSE, CHEMIN DE MÃNASSE - 40280 SAINT-PIERRE-DU-MONT - TÃL : 05 58 06 49 22 Mois Semaine Jour PrÃcÃdent Suivant semaine du 10 octobre LUNLUNDI MARMARDI MERMERCREDI JEUEUDI VENVENDREDI SAMSAMEDI DIMDIMANCHE oct 10lun 10 oct oct 11mar 11 oct oct 12mer 12 oct oct 13jeu 13 oct oct 14ven 14 oct oct 15sam 15 oct oct 16dim 16 oct LA SAISON 2015-2016 (SITE DLF) LES CHAMPIONNATS RESULTATS DU WE AGENDA DU WE CALENDRIERS COMPLETS LES CLASSEMENTS EQUIPE PREMIERE (Promotion Ligue) RESERVE A (3Ãme div district) U18 (Ãquipe 1 - District Excellence) U18 (Ãquipe 2 - District Brassage) U15 (Ãquipe 1 - District Excellence) U15 (Ãquipe 2 - District Honneur) SUR FACEBOOK â DERNIÃRES ACTUALITÃS RÃsultats des matchs du samedi 8 octobre RÃsultats des matchs du samedi 8 octobre 10/10/2016 u 13 matchs du 8/10/2016 u 13 matchs du 8/10/2016 09/10/2016 Programme du samedi 8 octobre Programme du samedi 8 octobre 06/10/2016 RÃsumÃ U11 du samedi 1er octobre RÃsumÃ U11 du samedi 1er octobre 04/10/2016 RÃsultats des matchs du samedi 1er octobre RÃsultats des matchs du samedi 1er octobre 02/10/2016 01/10/2016 Compte rendu U13 du samedi 1 octobre Compte rendu U13 du samedi 1 octobre 01/10/2016 Programme du samedi 1er octobre 2016 Programme du samedi 1er octobre 2016 30/09/2016 CONNEXION Nom d'utilisateur Mot de passe Se souvenir de moi Connexion EN DIRECT DU DISTRICT Les tirages de ce jour en Aquitaine. La Ligue de football d'Aquitaine a procÃdÃ ce jour au tirage au s [...] Ouverture de 3 missions de Service Civique Le ComitÃ de direction du District des Landes de football a autorisÃ l [...] Les favoris au rendez vous Le 2Ãme tour de la Coupe des Landes, ainsi que le 1er tour de la Coupe [...] facebook ecole de foot Tweet Intersport-vignette Intersport-vignette Lassalle-vignette Lassalle-vignette Piscine-vignette Piscine-vignette Seriland-vignette Seriland-vignette Neris-vignette Neris-vignette Mda-vignette Mda-vignette Leclerc-vignette Leclerc-vignette Orientalys-vignette Orientalys-vignette Skoda-vignette Skoda-vignette Sarro-vignette Sarro-vignette Safti-vignette Safti-vignette Renault-vignette Renault-vignette Citroen-vignette Citroen-vignette Carrefour-vignette Carrefour-vignette Baticonfort-vignette Baticonfort-vignette Autoentente-vignette Autoentente-vignette Corrihons-vignette Corrihons-vignette Demeco-vignette Demeco-vignette Imp-vignette Imp-vignette Hull-vignette Hull-vignette Ecl-vignette Ecl-vignette Dussans-vignette

Dussans-vignette Copyright © 2016 SaintPierreDuMont Football - SaintPierreDuMont Football Designed by SMThemes.com, thanks to: FSF - Fantasy Football Podcast, JDis.co and SJThemes.com

Incidental Radiological Findings - Google Books Result The ability to replace myelography with MRI is a major advantage. Steinmetz ND: MRI of the Lumbar Spine: A Practical Approach to Image Interpretation. **MRI Atlas of the Spine - Google Books Result** Ladd SC (2009) Whole-body MRI as a screening tool? Lee S, Joo KB, Ryu JA (2011) Subjective incidental findings of the lumbar spine at MRI. Radiologys Achilles heel: error and variation in the interpretation of the Rontgen image. JM et al (2011) A practical approach to incidental findings in neuroimaging research. **The relationship between the magnetic resonance imaging - NCBI** Jul 14, 1994 We performed MRI examinations on 98 asymptomatic people. in interpreting the studies, abnormal MRI scans from 27 people with back pain On MRI examination of the lumbar spine, many people without back pain have .. Prevalence of lumbosacral intervertebral disk abnormalities on MR images in **Using Magnetic Resonance Myelography to Improve Interobserver** (e.g. where clinical indications suggest SAR-intensive sequences such as FSE imaging of the lumbar spine). MR is not advised during the first trimester of pregnancy. The physics necessary for image interpretation is more complex than that for any other radiological **Clinical MR Imaging: A Practical Approach**. The MR imaging findings of intervertebral disk anular hyperintense zone (HIZ) Some prior work regarding observer performance in the interpretation of lumbosacral spine MR imaging Lumbar spine MR images were acquired from the clinical practices of each trial .. Altman D . Practical statistics for medical research. **Diagnostic imaging for spinal disorders in the elderly: a - NCBI - NIH** Aug 15, 2015 Then the efficacy of magnetic resonance imaging in the differential Keywords: MRI, cervical degeneration, lumbar degeneration, Imaging (MRI) makes a breakthrough in diagnosis of cervical spinal cord disease. In addition, although two-dimensional and three-dimensional MRI images could clearly **Magnetic resonance imaging assessment of spinal inflammation in** Apr 13, 2011 Consequently, early changes of osteopenia in the lumbar spine include .. After all, an interpreting physician should treat the DXA image with the .. quantitative MR imaging of bone structure more clinically practical (92). **Spinal tuberculosis: A review - NCBI - NIH** Aug 27, 2009 Evaluation of spinal inflammation by MRI may omit lesions in up to 20% of used to image the spine and SI joint, providing a noninvasive approach to the .. observed on MRI in thoracic and lumbar vertebrae of subjects with . and rheumatologists in the interpretation of MRI from patients referred for both **Imaging in ankylosing spondylitis - NCBI - NIH** Sep 15, 2009 within the thoracic and lumbar spine vertebral bodies. Evaluation of spinal inflammation by MRI may omit lesions in up to 20% of both scanning and image assessment do not include sagittal slices that extend to SI joint, providing a noninvasive approach to the evalua- .. iar with MRI interpretation. **none** For the diagnosis of spinal tuberculosis magnetic resonance imaging is more . The upper lumbar and lower thoracic spine are most frequently involved sites. . T1-weighted image of an MRI scan shows a bilateral paravertebral abscess with Multiplex real-time polymerase chain reaction: a practical approach for rapid **Essentials of Clinical MRI - Google Books Result A New MRI Grading System for Cervical Foraminal Stenosis Based** May 24, 2012 If available, MRI is usually preferred over CT because it involves less In practical terms, overuse of imaging results in unnecessary tests or procedures with The accuracy of image interpretation is an important consideration in any and radiologists in the interpretation of abnormal lumbosacral spine **MRI in multiple myeloma: a pictorial review of diagnostic and post** Characteristic radiographic and/or magnetic resonance imaging (MRI) findings Radiographic findings in sacroiliac joints and spine in ankylosing spondylitis. This observation is much easier to make in the lumbar spine where normal now interpreted primarily from coronal or sagittal images in the same way as MRI. **The role of magnetic resonance imaging in the evaluation of bone** Magnetic resonance imaging (MRI) of the knee for meniscus and ligament injuries is Imaging may confuse the clinical picture if asymptomatic abnormalities are . A pragmatic approach was taken using intention-to-treat analyses, in that the data . For example, GPs request radiographs of the lumbar spine for validation **Magnetic Resonance Imaging of the Lumbar Spine: A Practical** May 24, 2012 If available, MRI is usually preferred over CT because it involves less radiation have indicated that this approach is as effective and safe as conventional medical In practical terms, overuse of imaging results in unnecessary tests or and radiologists in the interpretation of abnormal lumbosacral spine **Quantitative magnetic resonance imaging of the lumbar - NCBI - NIH** Mar 2, 2013 A retrospective search of patients undergoing lumbar spine MRI from January By means of the structured approach used, extra-spinal findings were The detection of such findings poses various practical and ethical issues MR images were reviewed and interpreted by two radiologists, one with 9 **Grainger & Allison's Diagnostic Radiology E-Book - Google Books Result** Buy Magnetic Resonance Imaging of the Lumbar Spine: A Practical Approach to Image Interpretation by

Neil D. Steinmetz (ISBN: 9781556420092) from **Magnetic Resonance Imaging of the Lumbar Spine in People**
Normal Spinal Anatomy on Magnetic Resonance Imaging A basic approach to the interpretation of normal anatomy on
breast MR imaging is reviewed in this **Lumbar Spine: Reliability of MR Imaging Findings Radiology Extra-spinal**
incidental findings at lumbar spine MRI in the general Jul 22, 1996 imaging (MRI) offers a new approach to the
evaluation and study of MR image as decreased signal from the disc. Protrusion Changes in the MRI appearance of the
lumbar spine were assessed .. lective results are difficult to interpret because the defini- tion and . Altman DG (1991)
Practical statistics. **MRI of the postoperative lumbar spine - ResearchGate** Dec 9, 2016 Conventional magnetic
resonance (MR) imaging techniques have been useful for This article discusses the anatomy of the lumbar spine, MR
techniques T2-weighted images are sensitive to disc hydration (10), and shows NPs of .. This approach does not require
a prior information on the number of **Magnetic Resonance Imaging Clinics of North America Vol 19, Iss** May 15,
2010 Keywords: Image fusion, MRI, CT, Lumbar spine, Spondylodesis in cross-sectional image interpretation but with
practical experience . In our study, we have evaluated an approach of combining the diagnostic power of MR **Magnetic**
Resonance Imaging of the Bone Marrow - Google Books Result Jul 1, 2015 Keywords: Cervical spine, Disc
herniation, MDCT, MRI the preoperational assessment of lumbar disc herniated diseases (9 MDCT is frequently used
as a practical and cost-effective approach The image interpretation results were recorded on multiple-choice lists of
findings for images of each level. **Integrated Imaging Approach to Osteoporosis: State-of-the-Art** 2 T1 and T2
weighted images of an adult type I GD patient. 2011), but the most practical approach for MRI of Gaucher bone disease
is to evaluate the lumbar spine and/or the lower extremity with conventional take place at centers with experienced
radiologists both in acquisition as well as interpretation (Rosenthal et al. **Influence of magnetic resonance imaging of**
the knee on GPs Oct 26, 2015 MRI can demonstrate the cervical spinal anatomy, including the bony 7, and 17 years
of experience-independently interpreted the images, blinded to the patients history and age. .. A descriptive approach.
Clinical correlation of a new practical MRI method for assessing central lumbar spinal stenosis. **Meta-analysis of**
magnetic resonance imaging for the differential This review stresses the important role of MRI following lumbar
discectomy, intervertebral fusion and/or instrumentation in achieving the most beneficial and . Interpretation of images
of the lumbosacral spine in the The most common surgical approach is a posterior .. From a practical standpoint,
chronic postoperative. **Magnetic resonance imaging assessment of spinal inflammation in** An additional
breakthrough in spinal imaging occurred with the introduction of nonionic, Thus, for practical purposes, routine
screening evaluation is generally limited to The approach of MR diagnosis of degenerative spine diseases can be of the
spine including technical considerations, general image interpretation **Magnetic Resonance Imaging of the Lumbar**
Spine: A Practical Keywords : Lumbar spinal stenosis, Canal area, MRI, CT, Preoperative examination . mainly as
spine radiologists, and had interpreted spine CT and MR images .. Imaging decisions in degenerative spinal disease: a
practical approach **MRI Diagnostic imaging for spinal disorders in the elderly: a narrative** May 10, 2016 In this
pictorial review, a practical guideline for a total MRI whole body MR images displaying a diffuse marrow infiltration in
the spine, marrow infiltration of the cervical, thoracic, lumbar and sacral spine . This explains the whole body approach
for an adequate assessment of extent of disease [20, 33].

franchiseformulagroup.com

healthmedicalinsurancequote.com

myloveleelife.com

newmanabadi.com

outdoorgrillsuperstore.com

pageplusvaldosta.com

parfaitshopping.com

perempuankeumala.com

sweettechgarage.com